UPMC

University of Pittsburgh
Medical Center

Osteomyelitis in the patient with Diabetes Mellitus

Dane K. Wukich MD

5th Annual
Multidisciplinary Management
of the High Risk Diabetic
Foot Conference

Diabetic Foot Osteomyelitis

- Present in 20% of DFU
- Increases the likelihood of amputation
- Diagnosis is not always easy
- Traditional treatment has been debridement of bone and soft tissue plus 4-6 weeks of antibiotics.

What is DFO??

- Soft tissue ulcer with drainage and :
  1. Plain radiographic changes
  2. Localized bone scan uptake
  3. Bone at base of ulcer that can be seen, probed or palpated
  4. Positive bone culture
  5. Positive bone histopathology

Game and Jeffcoate: 2008

- “Observational studies of osteomyelitis such as this [study] are weakened by difficulties of case definition, especially as there are currently agreed criteria by which bone infection, when clinically suspected, can be either diagnosed or excluded with confidence”

Pathophysiology

- Almost always occurs by direct seeding from an associated ulcer
- The ulcer may stem from a neuropathic ulcer to penetrating trauma (a needle)
- Arterial insufficiency may play a role but neuropathy is the key
- Most often affects bones where ulcers are most common

Pathophysiology

- Adjacent soft tissue infections violates periosteal barrier
- Microorganisms devitalize bone cortex
- The bone marrow gets colonized and osteomyelitis develops (bone abscess)
- Bacteria are usually the same that cause diabetic foot infections

Risk Factors for DFO

- Neuropathy
- PVD
- Structural deformity
- Trauma
- Limited Joint Mobility
- **Presence of an ulcer**

UPMC | University of Pittsburgh Medical Center

Definitions

- **Involucrum**: bone that forms under the periosteal flap
- **Sequestrum:** dead, necrotic infected bone that may be separated
- **Biofilm:** prevents antibiotics from getting to the bug

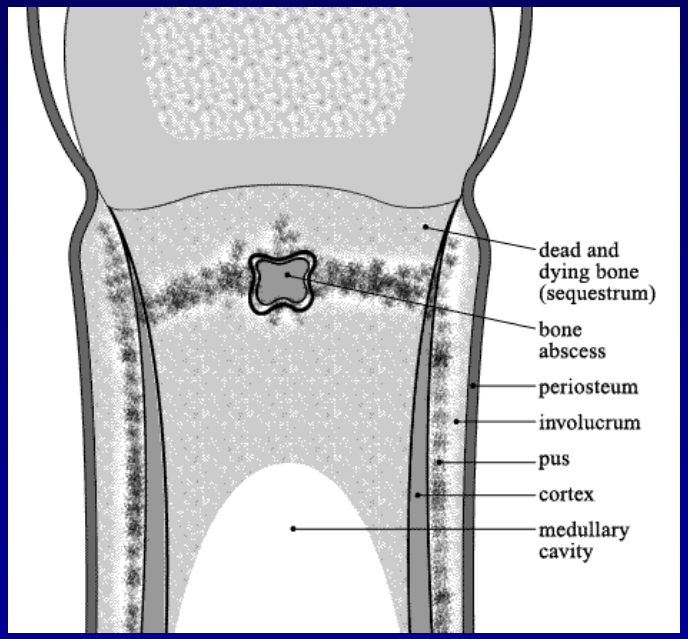

Anatomical locations

- Toes 45%
- Metatarsals 45%
- Calcaneus 4.5%
- Midfoot 1.5%

History

- Always consider osteomyelitis in an ulcer that fails to heal
- Patient may report that a piece of bone has extruded from the wound
- Patients may not have systemic signs of infection unless it is limb threatening

Physical Exam

- Larger and deeper ulcers are more likely to have osteomyelitis than ulcers that are less than $2cm^2$ and less than 3mm deep
- Probe to bone test has evolved over time, although exposed bone raises the likelihood of osteomyelitis

Probe to bone test

- Grayson 1995
- Shone 2006
- Lavery 2007

UPMC | University of Pittsburgh Medical Center

Probe to bone :Grayson 1995

- Sensitivity 66%
- Specificity 85%
- **Positive Predictive Value 89%**
- Negative Predictive Value 56%

- Conclusion was that if it probed to bone then DFO was present (66% of patients had osteomyelitis)

Probe to bone: Shone 2006

- Sensitivity 38%
- Specificity 91%
- Positive Predictive Value 53%
- **Negative Predictive Value 85%**

- Conclusion: The PPV was not as high because of less osteomyelitis was present in these patients (20%)

Probe to bone:Lavery 2007

- Sensitivity 87%
- Specificity 91%
- Positive Predictive Value 57%
- **Negative Predictive Value 98%**

- Conclusion: If it doesn't probe to bone it probably does not have osteomyelitis (12% of the study patients had DFO)

UPMC | University of Pittsburgh Medical Center

Imaging Studies

- Plain radiographs may be *negative* in the first few weeks of infection
- May be difficult to interpret in the presence of Charcot neuroarthropathy
- Bone scans and White Blood Cell Scans are more sensitive than plain radiographs but lack specificity

MRI is most useful modality

- Evaluates both bone and soft tissue
- May be difficult to distinguish between Charcot and osteomyelitis
- Focal decrease in bone signal in T1 and focal increase in bone signal in T2

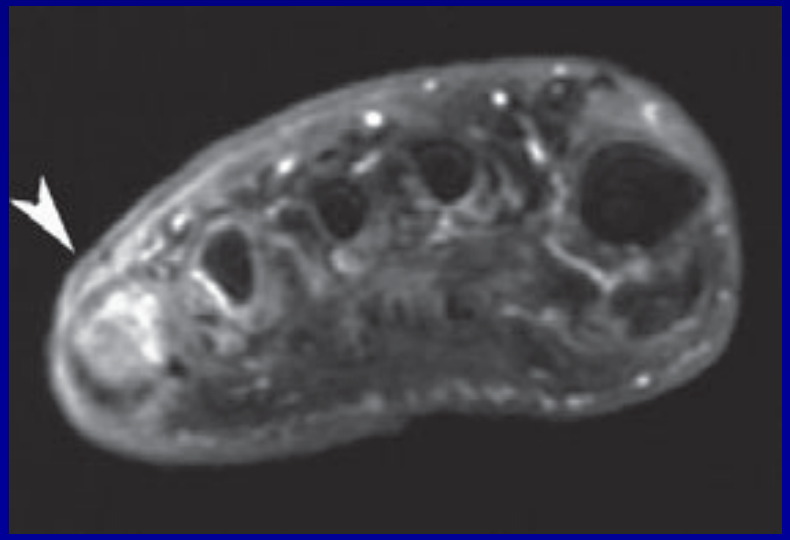

UPMC | University of Pittsburgh Medical Center

Laboratory Findings

- ESR greater than 70mm is associated with a positive likelihood ratio of having osteomyelitis
- WBC may not be elevated
- CRP is usually elevated in bone infection but not in Charcot

- *Butalia et al: JAMA 2008*

Histopathology

- Osteonecrosis
- Infiltration of neutrophils (acute)
- Infiltration of plasma cells and lymphoctyes (chronic)
- *Bone biopsy in concert with bone cultures are considered the gold standard in making the diagnosis*

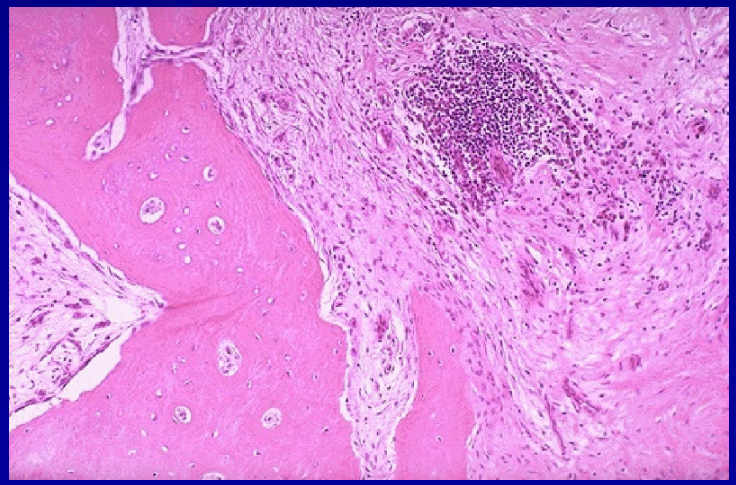

UPMC | University of Pittsburgh Medical Center

Cultures

- Ideal to be off antibiotics for > 48 hrs
- Superficial swabs of ulcers only correctly identify bone pathogens in 30%
- Even deep soft tissue cultures only correctly identify 36% of bone pathogens
- ***<u>Must take bone cultures</u>***

Treatment

- Current treatment protocols are not guided by high level of evidence
- Traditional treatment utilizing surgery may not be necessary in all cases

- Diabetic foot osteomyelitis: a progress report on diagnosis and systematic review. Diabetes Metabolism Research Review 2008

Definitions

- **Debridement:** removal of devitalized, infected or necrotic soft tissue
- **Conservative surgery:** removal of infected bone with or without soft tissue debridement
- **Amputation:** removal of a part

Definitions

- **<u>Minor Amputation:</u>** removal of bone and soft tissue distal to the ankle
- **<u>Major Amputation:</u>** removal of bone and soft tissue proximal to the ankle

UPMC | University of Pittsburgh Medical Center

Diabetologia 2006

DFO: Ha Van et al: Diab Care 1996

Medical Therapy

- 57% healed
- Healing time: 462 days
- Antibiotic use: 246 days

Conservative Surgery

- 78% healed
- Healing time: 181 days
- Antibiotic use: 111 days

- Surgery included limited resection of a phalanx or metatarsal

Non-Surgical Treatment

- Usually involves limited or no debridement of the ulcer
- IV antibiotics followed by oral antibiotics
- No data exists to support the superiority of IV versus oral therapy
- No data exists to support the duration of antibiotic therapy

Oral Therapy for DFO

- 79 patients (93 episodes of DFO)
- Pts treated with a mean of 3 oral agents
- Mean duration of treatment was 40 wks
- 80% were put into remission
- Mean relapse free followup was 50 wks

- *Embil et al: Foot and Ankle Int. 2006*

Non Surgical Management

- 113 patients
- 20% received initial IV therapy followed by oral therapy
- 80% received only oral therapy
- Mean oral therapy was 9 wks and mean IV therapy was 2 wks

- *Game and Jeffcoate: Diabetologia 2008*

Non Surgical Management

- Remission achieved in 59% without surgery while 31% recurred (35 pts)
- 27/ 35 recurrent patients achieved another remission with antibiotics alone
- Overall, 82% of the patients achieved remission

- *Game and Jeffcoate: Diabetologia 2008*

Nonsurgical DFO Tx of 50 pts

- 28 pts (56%) were initially hospitalized
- 22 pts (44%) were treated as outpatients
- 32 pts (64%) achieved remission
- Therapy based on bone cultures (81%) had significantly higher remission than non bone culture therapy (50%)

- *Senneville et al: Diabetes Care 2008*

Non operative treatment of DFO: Remission Rates

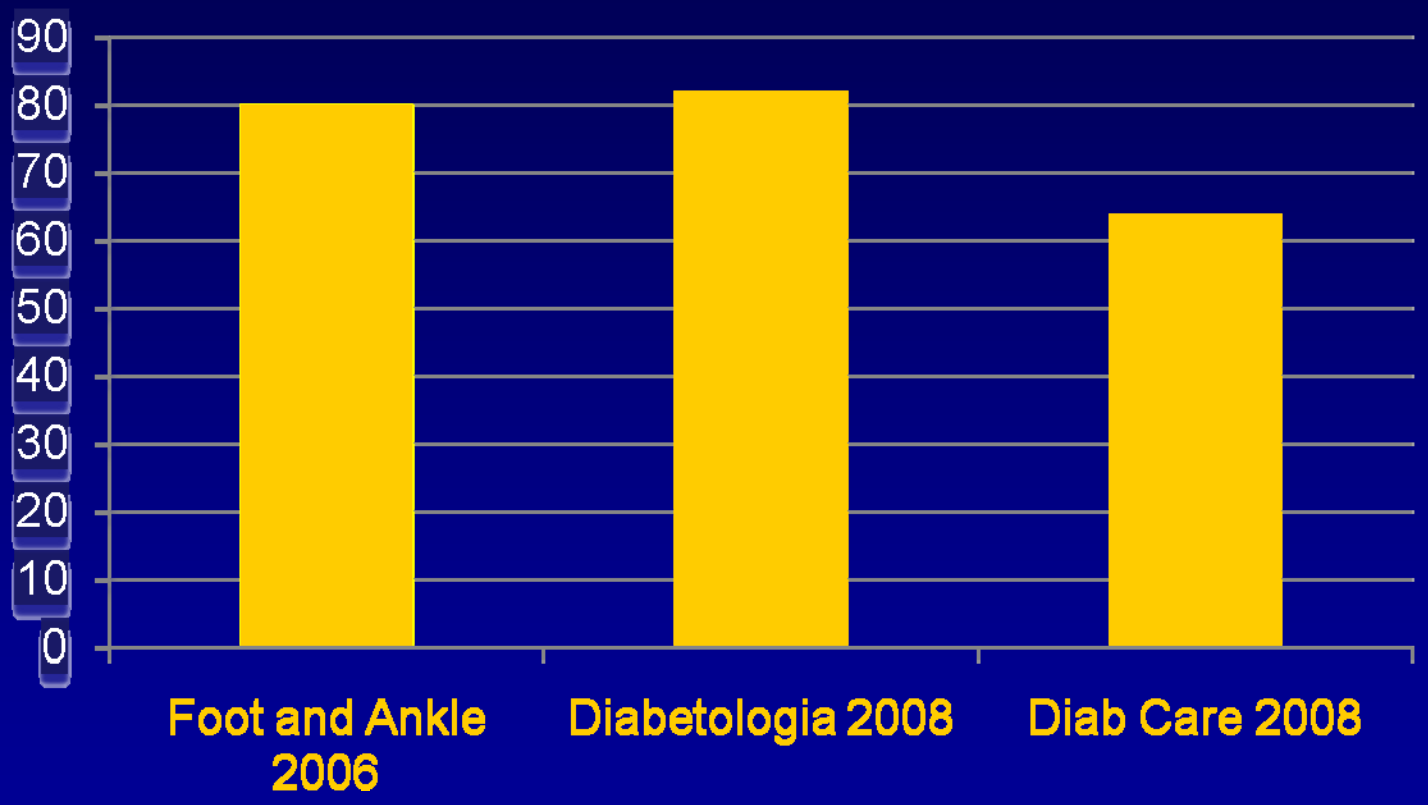

UPMC | University of Pittsburgh Medical Center

Non-Surgical Treatment

- Broad spectrum antibiotic coverage if not guided by positive cultures
- IV aminoglycoside
- IV ampicillen/sulbactam
- Ampicillen/clavulinic acid
- Clindamycin
- Ofloxacin/Ciprofloxacin

Ulcer Debridement

- Regardless of osteomyelitis treatment (nonsurgical versus surgical), all infected ulcers should be treated with debridement to remove pus and non viable tissue
  1. Bedside debridement
  2. Clinic debridement
  3. OR debridement

Absolute need for surgery

- Failure of nonsurgical management
- Necrotizing Fasciitis
- Deep soft tissue abscess
- Gangrene accompanying osteomyelitis
- Worsening clinical situation in face of nonoperative management (bacteremia, fever, tachycardia, hypotension, vomiting)

UPMC | University of Pittsburgh Medical Center

Non emergent surgery

- Compromise of the soft tissues
- Loss of mechanical function or integrity of the osseous support
- Want to avoid prolonged antibiotics

UPMC | University of Pittsburgh Medical Center

Surgical Treatment

- Debride to bleeding, viable bone
- Resect infected bone as needed while preserving foot function
- Partial foot amputation is preferred to transtibial amputation
- Surgery may involve amputation, arthroplasty or exostectomy

Surgical treatment of DFO

- Antibiotic use for 2-6 weeks
- Recommend leaving the wound open
- Two stage debridement
- Delayed primary closure
- Negative pressure therapy
- Skin grafting or Flaps
- Antibiotic impregnated cement or pellets

Outcome of surgical treatment

- 185 diabetic patients
- 49% conservative surgery
- 42% minor amputation
- 9% major amputation
- Risks of failure in conservative surgery included the presence of exposed bone, presence of ischemia or necrotizing soft tissue infection

UPMC | University of Pittsburgh Medical Center

Diabetologia 2008

Multidisciplinary Approach

- Plastic Surgeons
- Vascular Surgeons
- Orthopaedic/ Podiatry
- Infectious Disease
- Endocrinology
- Cardiology
- Nursing

UPMC | University of Pittsburgh Medical Center

DEPARTMENT OF ORTHOPAEDIC SURGERY 100 UNIVERSITY OF PITTSBURGH

The goal is remission

- Nobody refers to a cure when treating osteomyelitis with medical treatment or limb sparing surgery
- Amputation is the only way to effectively cure the disease

UPMC | University of Pittsburgh Medical Center

- The “official” orthopaedic color is **pink**

- A combination of blood, pus and tears

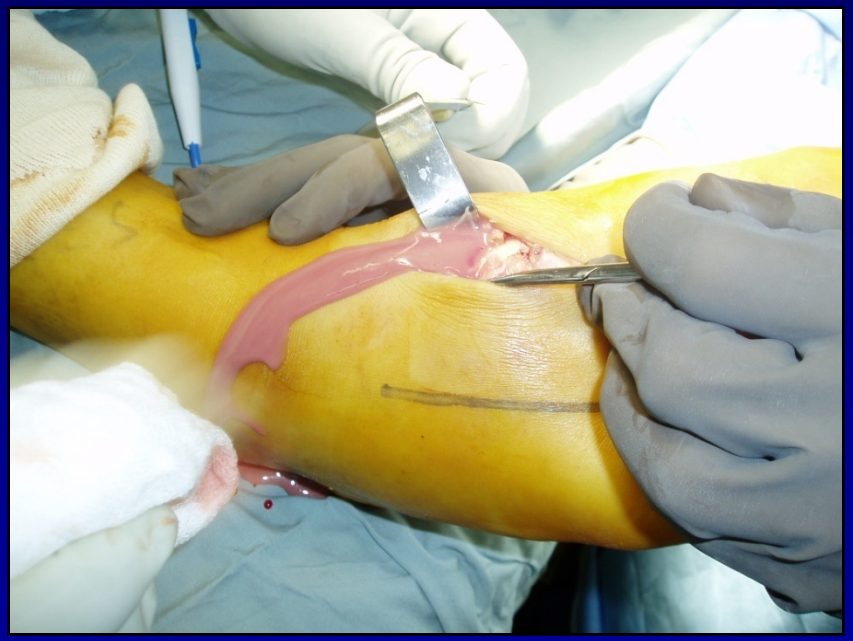

UPMC | University of Pittsburgh Medical Center

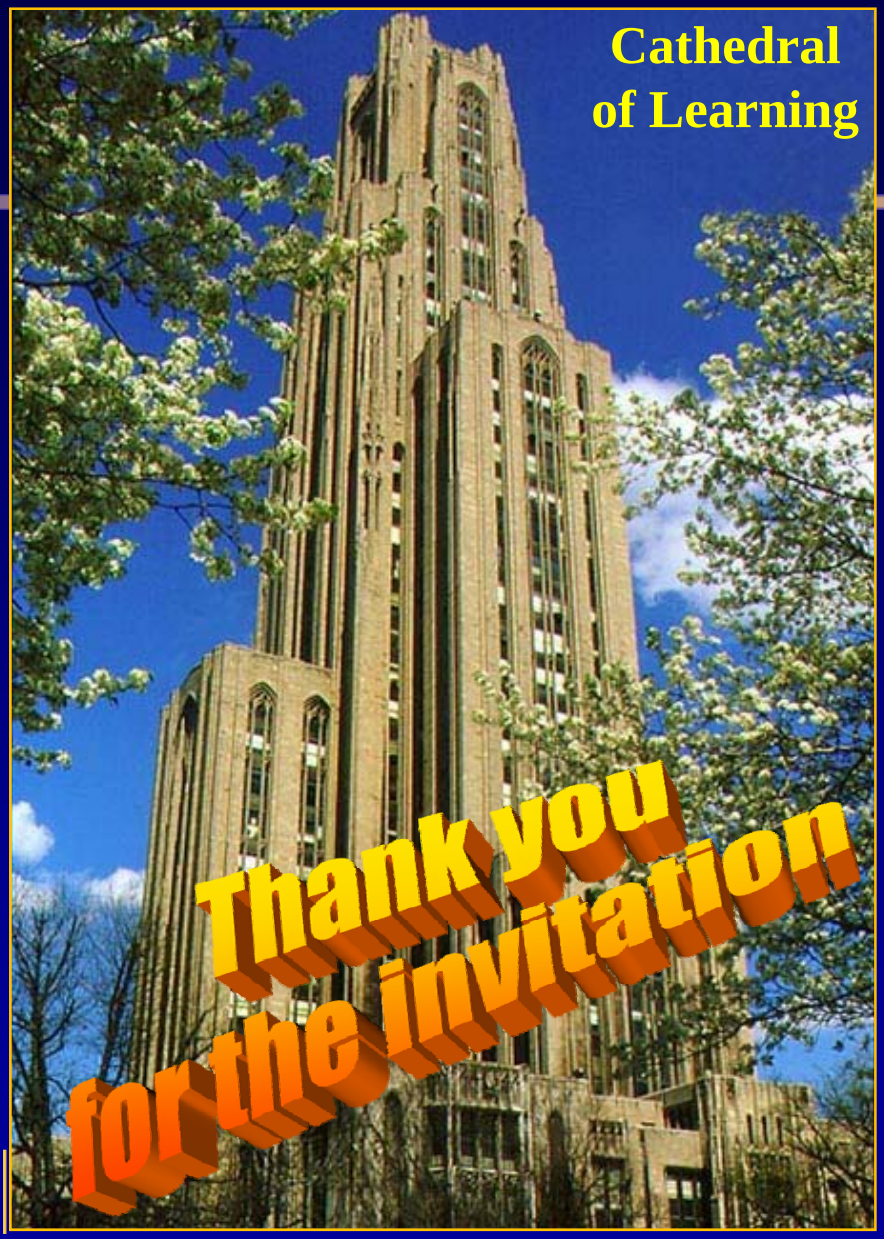

UPMC